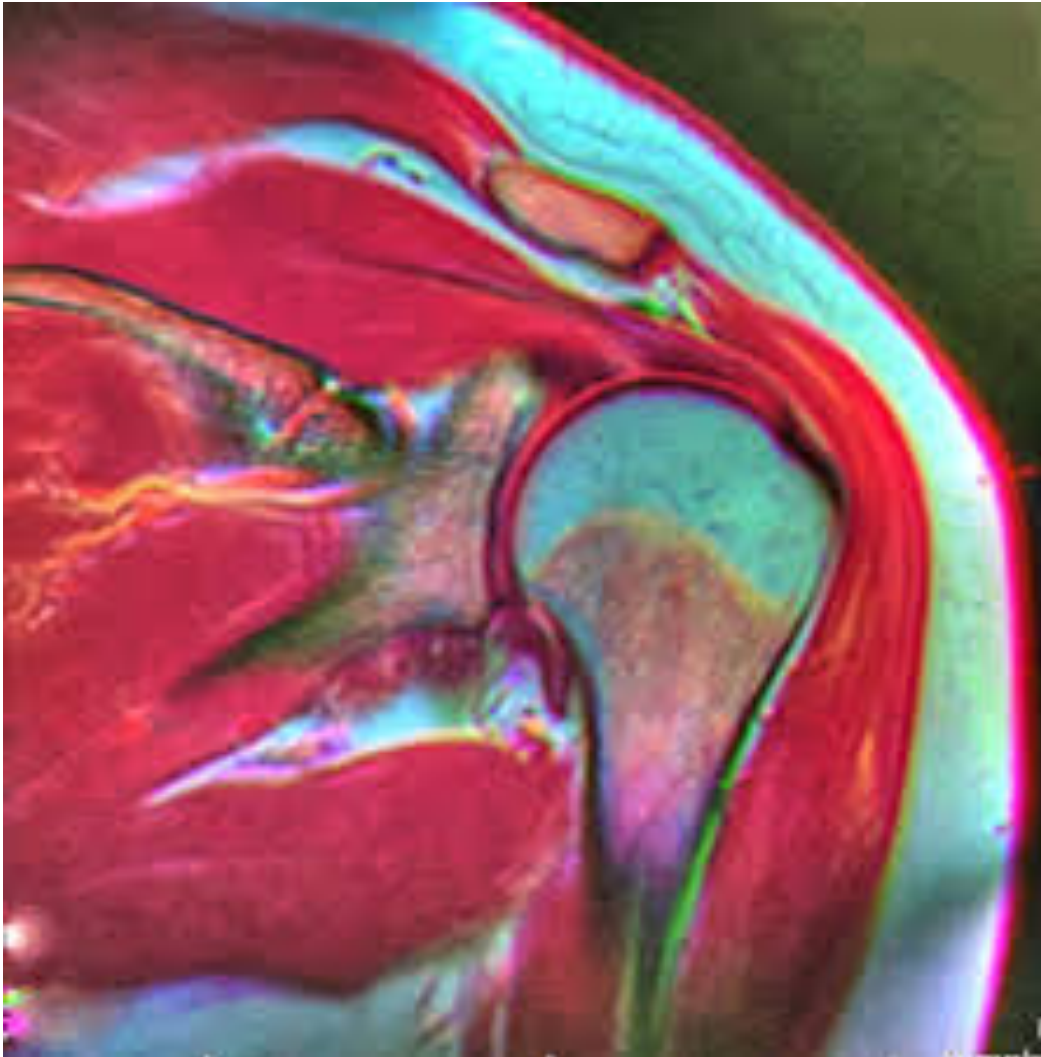


Interpreting MRI Reports



A Primer for Lawyers: The Shoulder

Vern Prochaska, MD

Greene Lyon Consulting

Introduction

The shoulder is a complex joint that allows for a huge range of motion. Certain aspects of its anatomy render it prone to injury and degenerative changes, making it one of the more common reasons for musculoskeletal pain and disability. Here in North Dakota, for example, the shoulder ranks fourth in Workers Compensation claims by body part at 7.2%, following low back (11.9%), fingers (10.9%) and knee (7.6%).

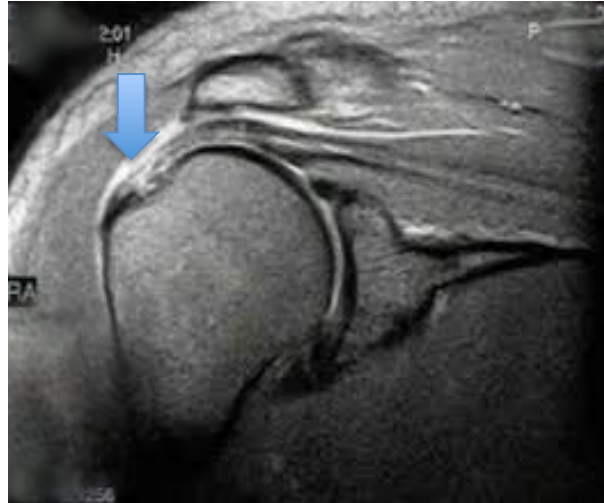
All that shoulder pain leads to a lot of shoulder MRIs and some often confusing and less than straightforward reports. The ideal report gives you a nice black and white answer: torn or not torn, healed or not healed, acute or chronic. Unfortunately MRIs are mostly shades of grey and the reports can be too.

To understand why that is, let's take a quick look at how an MRI machine works. The images produced by MRI machines are basically maps of the hydrogen atoms in the body. Through the use of a strong magnetic field and radiofrequencies the machine causes the hydrogen atoms to give off a small radio signal that can be detected. The signals are plotted on a grey scale to make the images. Since hydrogen is abundant in water and fat, tissues with high concentrations of these light up on the images. This is usually described as having increased signal or signal intensity on the report.

Most diseases and injuries result in an increased amount of water in the tissues. Recognizing the abnormal signal intensity doesn't guarantee a diagnosis, however. Different

conditions can look the same on MRI. For instance, rotator cuff degeneration and partial tears cannot be distinguished reliably.

The portion of the cuff shown here could be described a number of ways: degenerative, partial tear, interstitial tear, tendinosis or tendinopathy.



In the following sections I will go over some of the more common findings on shoulder MRIs and hopefully provide some helpful tips. The goal is to make you more aware of what the reports do and don't say about the condition of your clients' shoulder.

The following two pages are an example of a typical shoulder MRI report. If you read *A Primer for Lawyers: Part One* you will recognize the first part of this report. The Clinical Information, Comparison and Technique sections were covered in that primer. We are going to get into the FINDINGS and IMPRESSION sections now. You don't need to get bogged down in the details of the example. We'll cover the majority of the terms in it as we go.

Acme Diagnostic Imaging

**100 1st Street
Hometown, USA
Phone: 555-555-5555**

**Patient: John Doe
DOB: 12/10/1962
File #: 98765
Physician: Dr. Jones
Exam: MRI left shoulder
Date: 10/01/2017**

Clinical Information: Fall onto left shoulder 08/03/2017, possible rotator cuff tear

Comparison: None

Technique: Imaging performed through left shoulder per protocol including axial PD FS, coronal PD FS and PD, sagittal T1 and PD FS using 3T magnet without contrast.

FINDINGS

Rotator Cuff: There is moderate tendinosis with minimal articular sided fraying in the distal supraspinatus tendon. Increased signal can be seen at the tendon insertion on images 10 thru 12 of series 4. No full thickness tear or retraction is seen. The subscapularis, infraspinatus and teres minor are normal in appearance.

Biceps: There is mild tendinosis of the long head of the biceps within the bicipital groove.

Muscles: the cuff musculature demonstrates minimal loss of muscle bulk and no fatty infiltration is appreciated.

Subacromial Bursa: Mild bursitis is present.

Acromion/AC Joint: There is marrow edema within the distal clavicle and periarticular portion of the acromion. There is increased fluid present within the AC joint and mild pericapsular edema. No elevation of the distal clavicle and no fracture. Type II acromial configuration is noted with slight lateral downsloping.

Glenohumeral Joint/Labrum: There is increased signal within the superior labrum with fluid undermining the long head biceps anchor consistent with a type II SLAP lesion. No Bankart or other labral abnormalities are seen. Low grade chondral

thinning is seen throughout the glenohumeral joint, no full thickness loss. A moderate joint effusion is present. There are no intra-articular loose bodies.

Bone Marrow: Mild edema is present within the greater tuberosity. No fracture is seen. The remainder of the marrow is unremarkable.

IMPRESSION

- 1. There is moderate tendinosis of the distal supraspinatus with minimal articular sided fraying. A partial thickness or interstitial tear cannot be excluded.**
- 2. There is mild tendinosis of the biceps tendon within the groove.**
- 3. There is marrow edema in the distal clavicle and adjacent acromion. There is fluid within the AC joint and pericapsular edema. These changes may be stress related versus a grade I sprain of the AC joint.**
- 4. There is a type II SLAP lesion.**
- 5. Mild subacromial bursitis.**
- 6. There is edema present within the greater tuberosity consistent with a bone contusion.**

Rotator Cuff

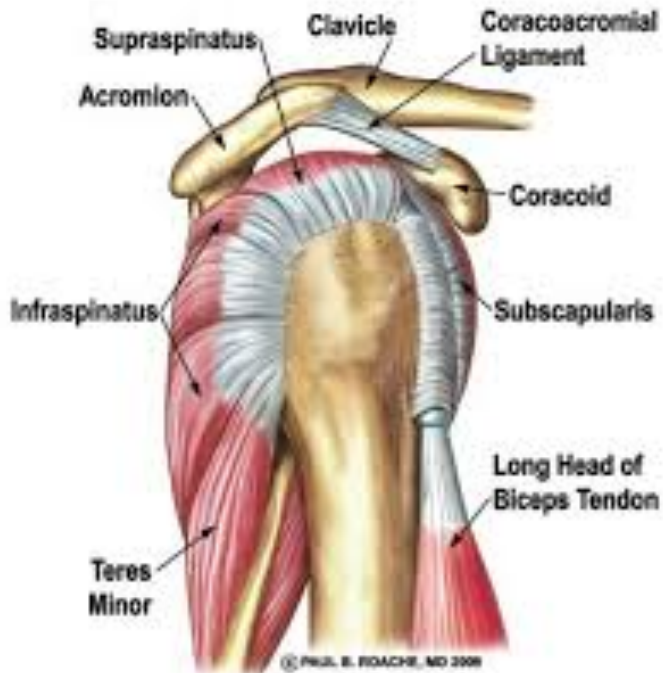
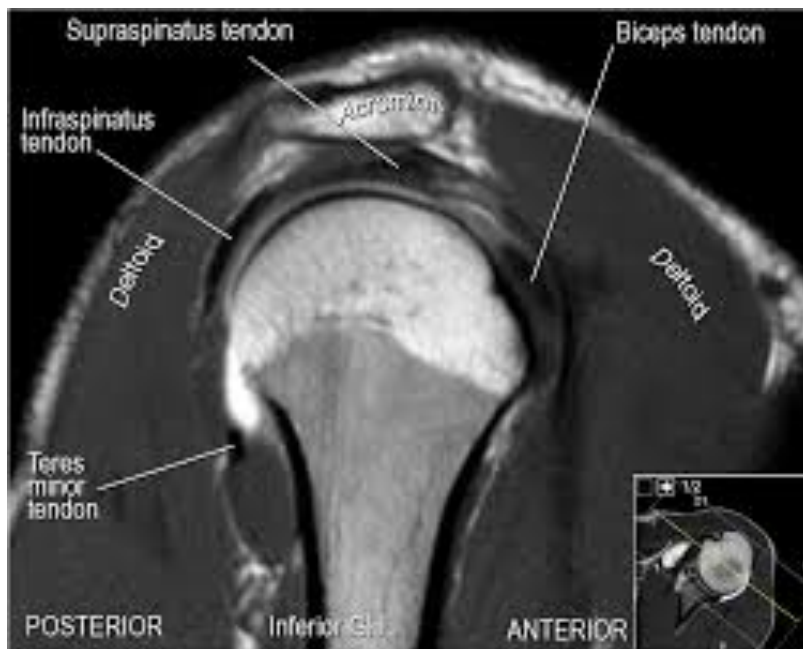
Illustration of Rotator Cuff viewed from the side

Courtesy of Paul B. Roache, MD 2009

The majority of shoulder MRI studies are done to evaluate problems arising from the rotator cuff tendons. The cuff is made up of four tendons that surround the front, top and back of the humeral head. The supraspinatus tendon on top is the most common pain generator. Whenever someone tells you they have had a rotator cuff repair, it's almost always the supraspinatus or combination of supraspinatus and infraspinatus that was fixed.

Tendons are very dense tissues with very little water content. Because of this, they normally have extremely low signal, therefore appear dark on MRI images. Increased signal in a tendon means something is wrong.



Normal MRI of shoulder, side view

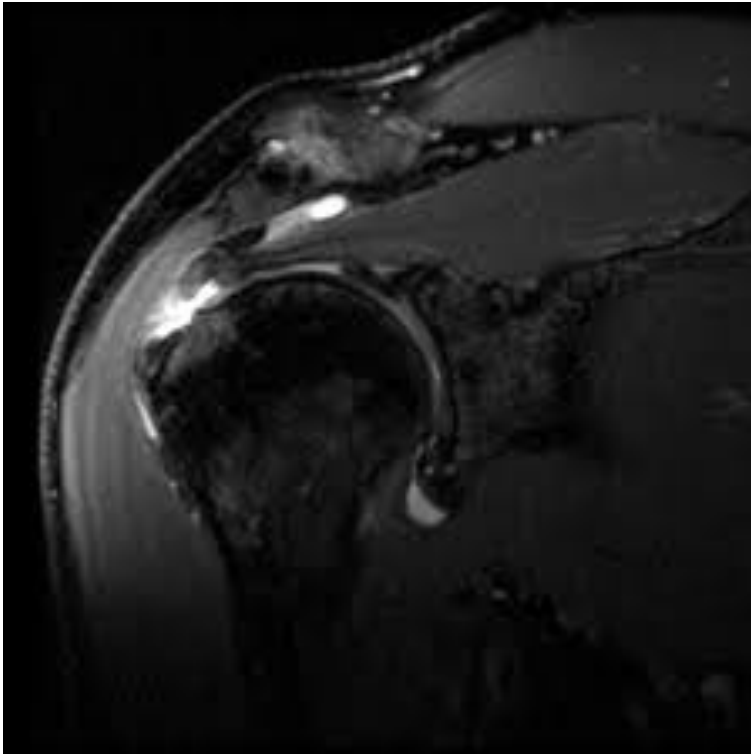
Courtesy of the Radiology Assistant

What does the report say about the tendon? You may see a couple of the terms I've mentioned already – tendinosis and tendonopathy. These terms are synonymous and mean that the tendon just doesn't look normal. They are non-specific terms that can include degenerative breakdown or interstitial tears. Interstitial tears are tears that occur within the substance of the tendon while the tendon remains attached.

Partial thickness tears can have a similar appearance but the term is usually used when at least a portion of the tendon has become detached from the bone. The images will show a gap in the tendon that doesn't go all the way through. Partial tears can be on the top of the tendon (bursal side) or on the undersurface (articular side).

Getting a more definitive diagnosis in the IMPRESSION section is possible if other findings or clinical history provide clues. Tendinopathy in a 32 year old heavy laborer is likely to be diagnosed as an interstitial tear. The same appearance in a sedentary 65 year old may get a diagnosis of tendon degeneration.

The description of full thickness cuff tears usually includes the tendon(s) involved and the size. The report may give an actual measurement of the amount of retraction of the tendon edge from the bone. Often the size is categorized as small (less than 1cm), moderate (1-3cm), large (3-5cm) and massive (>5cm). It should be no surprise that larger tears are more difficult to repair and have less favorable outcomes. Massive tears may not be repairable.



MRI of moderate sized cuff tear

Acute vs. Chronic Tears

Determining causation in cuff injury cases often hinges on being able to establish when the tear occurred. Unfortunately, there are no accepted guidelines for diagnosing an acute cuff tear by MRI alone. There are a couple of findings that can help, however. A description of edema in the rotator muscle or in the bone around the normal attachment site of the tendon suggests an acute traumatic tear. A wave-like kinking of the cuff has also been reported in acute traumatic tears. The radiologist is unlikely to include this finding in the report, so you may have to ask the treating physician if it is present on the images. Adding to the dilemma is the fact that these findings may be present in tears due to falls, but not in acute tears from lifting or pulling.

Older tears are more likely to have findings of cuff muscle atrophy and fatty infiltration. Here again, there are no definitive guidelines. The amount of retraction of the tendon has not been shown to correlate to timing of the tear. Long-standing cuff tears will typically have a combination of significant atrophy, fatty infiltration, larger tears and often a high riding humeral head.

Trying to establish the cause of a cuff tear is also complicated by the natural tendency for the cuff tendon to breakdown. The rotator cuff is prone to breakdown over time without injury, and sometimes without pain. A cuff tear can be found in almost 30% of people over 60 years of age that don't have pain. In people between 40 and 60 years old, 4% will have a full tear and 24% a partial tear. Full thickness tears in people younger than 40 are very rare without an external cause and only 4% will have partial tears.

Previous Cuff Repair

Interpretation of MRI images of a rotator cuff that has been previously repaired is even more difficult. The presence of scar tissue, sutures running through the tendon and suture anchors used in the repair can all affect the appearance of the tendon. The time interval between the repair and the MRI is also a big factor. Failure

of the repair or large recurrent tears can be seen on MRIs done soon after the surgery. However, incomplete healing, partial tears and small full thickness tears are difficult to distinguish within the first few months. It may take 6 months or more for an MRI to be useful in detecting some tears. MRI arthrograms can be helpful in cases with previous repairs.

Biceps Tendon

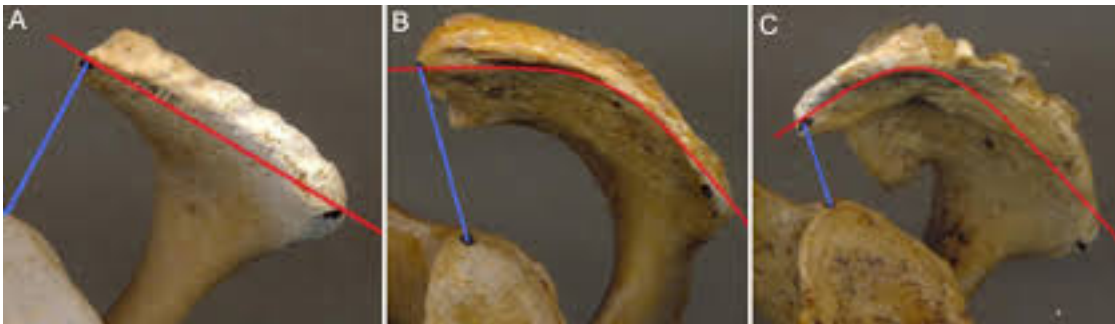
The long head of the biceps sits in a groove in the humeral head and is also subject to breakdown from wear and tear as it rubs over the edge of the bone. The MRI may describe tendinitis, partial tears or interstitial tears. Painful partial tears and tendon degeneration can be treated by releasing the tendon, a procedure called a tenotomy, or by anchoring it to the humerus, called a tenodesis. Complete tears of the biceps will be described as a biceps rupture and the groove will be empty. These types of biceps ruptures rarely cause long-term pain or loss of function so they are not typically addressed surgically. The exceptions may be athletes or young laborers. The tendon may also slip out of the groove and be described as a subluxation. Biceps tendon subluxation is usually treated in the same manner as partial tears, with tenotomy or tenodesis.



Bicipital groove in humeral head.

Acromion

The acromion or acromion process is a projection of bone from the shoulder blade that sits above the rotator cuff tendon. It can be a source of friction against the cuff, a condition known as Impingement. The report will typically comment on the shape of the acromion by classifying it as Type I, II or III. Type I is flat on the undersurface and allows more room for the cuff. Type II is curved and can impinge on the tendon. Type III is hooked and is frequently associated with impingement and cuff tears.



Acromial shapes: A. Type I, B. Type II, C. Type III

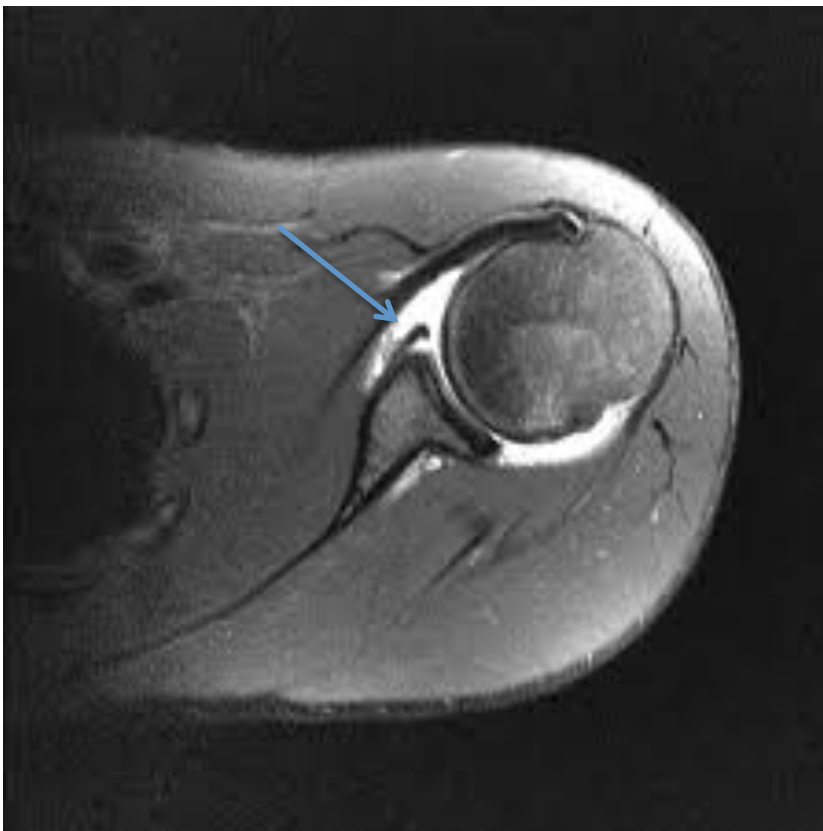Pictures published by Aragao et. al. in *Rev. bras. ortop.* vol.49 no.6 São Paulo Nov./Dec. 2014

If the shape classification is not given, the acromion may be described as down-sloping causing some degree of impingement. Impingement is a common shoulder condition that can be treated by physical therapy, NSAIDs, injection and activity modification. If conservative treatment is unsuccessful, surgically removing the portion of the bone rubbing on the cuff can help. This is almost always done arthroscopically in a procedure called an acromioplasty or sometimes called a decompression.

The Labrum

The glenoid labrum is the cartilage rim that runs around the edge of the shoulder socket. The bony portion of the socket, the glenoid, is

very shallow. The labrum deepens the socket somewhat and plays an important part in keeping the humeral head in place. Tears of the labrum can result in shoulder instability with subluxation and/or dislocation. There are a variety of tear configurations and types, many of which have acronyms and eponyms that can show up in the reports (see glossary at the end). Labral tears that cause instability or painful catching are typically repaired arthroscopically



MRI showing tear of anterior labrum

The biceps tendon attaches to, and becomes confluent with, the top of the labrum. The superior portion of the labrum where the biceps attaches is often called the biceps anchor. Reports may say “the biceps anchor is intact”, indicating that this portion of the labrum is not torn. Labral tears in this region are called SLAP tears (see glossary) and may be further described as types I–IV if sufficient detail can be seen on the images. Tears of the labrum, SLAP tears

in particular, can be difficult to see on MRI without an arthrogram. Treatment of SLAP tears depends on multiple factors including age and activity level of the patient and configuration and severity of the tear. It can range from non-operative treatment to repair or tenotomy of the biceps tendon.

Conclusion

I hope you found a few useful insights in this primer. My goal is to make you more familiar with the terms used in MRI reports and more comfortable interpreting them. The shoulder has some unique problems, such as Impingement Syndrome, that make it prone to degenerative conditions as well as work related injuries. Being able to distinguish between the two isn't always easy. Having an understanding of these issues lets you communicate more effectively with your clients, treating physicians and consultants.

GLOSSARY of terms, acronyms and eponyms used in shoulder MRI reports.

ALPSA lesion– Anterior Labroligamentous Periosteal Sleeve Avulsion.

A variation of the Bankart Lesion (see next) with a tear of the anterior labrum, but with an intact periosteal attachment.

Bankart lesion – Tear of the anteroinferior labrum and periosteum.

May have an associated glenoid rim fracture.

Bennett lesion – Mineralization of the posterior capsule/ligament.

Caused by chronic traction forces, usually seen in pitchers.

BHAGL lesion – Bony HAGLE lesion (see below).

Avulsion of a small fragment of bone with the glenohumeral ligament.

Buford Complex – Congenital absence of the anterosuperior labrum with a thickened middle glenohumeral ligament.

GLAD lesion – Glenolabral Articular Disruption.

Another variation of the Bankart lesion with a tear of the anterior labrum, but with a piece of articular cartilage attached to the torn labrum.

HAGL lesion – Humeral Avulsion of the Glenohumeral Ligament.

Occurs from a shoulder dislocation with the ligament torn from the humerus instead of the glenoid.

Hill-Sachs lesion – Impaction fracture of the posterior humeral head.

Occurs from an anterior shoulder dislocation.

PASTA lesion – Partial Articular Surface Tendon Avulsion.

Also called a rim rent tear, this is a common type of partial thickness cuff tear.

Os acromiale - An unfused portion of the acromion process.

During growth different parts of the scapula fuse together to form the adult bone. Failure of this growth center to fuse with the rest of the scapula results in a separate piece of bone. It is sometimes confused for a fracture and can cause impingement.

Reverse Bankart lesion - Same as a Bankart lesion but caused by a posterior shoulder dislocation.

Reverse Hill-Sachs lesion – Also known as a McLaughlin lesion, is an impaction fracture of the humeral head caused by a posterior shoulder dislocation.

Sublabral recess – Also called a sublabral foramen, this is a normal anatomic variant that can be mistaken for a SLAP lesion (see next).

SLAP lesion – Superior Labrum, Anterior to Posterior tear.

A tear of the superior attachment of the labrum running anterior and posterior to the biceps anchor.

Primers on the knee and spine are planned in the coming months if interest exists. Please let me know if you would like to see them. Reviews of topics other than MRIs are also possible. If you have a topic you would like to see covered I am always open to suggestions.

Your questions and comments are welcome.

Vern Prochaska, MD

vern.prochaska@GreeneLyonConsulting.com

www.GreeneLyonConsulting.com



GREENE LYON
CONSULTING

MEDICAL LEGAL SERVICES

